CONTRAST UNITS AND ENDOGRAPHIC METHODS

DR VALENTINA OPANCINA, MD, PHD

ASSOCIATE PROFESSOR

DEPARTMENT OF RADIOLOGY, FACULTY OF MEDICAL SCIENCES, UNIVERSITY OF KRAGUJEVAC

УНИВЕРЗИТЕТ
У КРАГУЈЕВЦУ

Objectives

- Introduction to the contrast media used during radiological examinations,
- Introduction to endographic methods in radiology
- Acquaintance with side effects and measures of prevention and treatment of side effects of contrast agents,

Contrast media

- Defines subtle differences in subject contrast
- Increases atomic number of area injected
- Results in a SHORTER scale of subject contrast

Subject Contrast

- Range of differences in the intensity of the x-ray beam, after it has been attenuated by the subject (patient).

- For LOW CONTRAST stucures:
- What can be done to attain medical information- see the difference between muscle, organs or vessels
- Define and outline – organ structure and function

- **CONTRAST MEDIA used to:**
- **enhance** subject contrast or render high subject contrast in a tissue that normally has low subject contrast

Why use contrast media

- Where considerable difference between the densities of two organs exists then the outlines of the structures can be visualised on a radiograph due to natural contrast.

  Similarly, if there is a difference between the average atomic numbers of two tissues, then the outlines of the different structures can be seen by natural contrast.

- However, if the two organs have similar densities and similar average atomic numbers, then it is not possible to distinguish them on a radiograph, because no natural contrast exists.

  This situation commonly occurs - it is not possible to identify blood vessels within an organ, or to demonstrate the internal structure of the kidney, without artificially altering one of the factors mentioned earlier.

Types of CM based on the machine

- Radiographic (Iodine based, Barium sulfate, Thorium dioxide – past)
- MR (Gadolinium)
- Ultrasound (CEUS – Contrast –enhanced ultrasound – microbubbles)

Contrast Media

Negative contrast	Positive contrast
(AIR OR CO_2)	(all others)
Radiolucent	Radiopaque
Low atomic # material	High atomic # material
Black on film	White on film

Types of Contrast Media

- Radiolucent-
- negative contrast agent
- x-rays easily penetrate
- areas- appear ____ on films

Negative Contrast Media

- **Air and gas**

- **complications**
- **emboli-air pockets in vessels**
- **lack of oxygen**

- Radiopaque-
- positive contrast agent-
- absorbs x-rays
- areas- appear ____ on films

Positive Contrast Agents

- BARIUM
- IODINES

Both + & - can be used in same study

2 BASIC TYPES OF CONTRAST material

- BARUIM Z# 56
- NON WATER SOLUABLE
- GI TRACT ONLY INGESTED OR RECTALLY
- KVP 90 – 120*

- IODINE Z# 53
- WATER SOLUABLE
- POWDER
- LIQUID
- INTRAVENOUS OR
- *Intrathecal*
- GI TRACT
- Also OIL based
- KVP BELOW 90*

Radiological Contrast media

- Iodine - provides radio-opacity

  (discovered treating syphilis in the 1920's with sodium iodide)

- Other elements of RCM molecule = carrier
  - ↓ toxicity, ↑ solubility of iodine, non-radioopaque

- All IV RCM
  - Benzene ring
  - 3 atoms of iodine at C 2,4,6 positions

- Classification
  - Ionic or non-ionic
  - High or Low osmolar
  - Monomeric or Dimeric

Osmolality

- Dependent solely on number of dissociated particles (not number of molecules).
- The closer the osmolality of RCM to that of plasma the better the tolerance.
- Osmolality is directly responsible for a number of clinically important effects. The sensations of heat and discomfort or even pain from contrast media are directly related to the osmolality.

Viscosity

- Resistance of a liquid to various forces (and hence to flow)
- Related to concentration of the Iodine in a contrast medium
- Inversely related to temperature
- Not related to pressure

Radiological Contrast Media

- 4 types RCM
  - Ionic monomer = high osmolar
  - Ionic dimer = low osmolar
  - Non-ionic monomer = low osmolar
  - Non-ionic dimer = iso-osmolar
- Distribution
  - Hydrophilic
  - Capillary permeability throughout extracellular compartment.
  - Filtered unchanged in glomerulus.
- Excreted - 90% by glomerular filtration in 12 hrs

Ionic Monomer RCM

- Iodine atoms = 3
- Osmotic particles = 2
- Ratio 3:2
- High osmolar 1550 mOsm /kg water
- e.g. Diatrizoate = Hypaque 50 (300 mg Iodine/ mL) Urografin, Gastrografin
- Metrizoate = Isopaque 370 (370 mg Iodine/ mL)

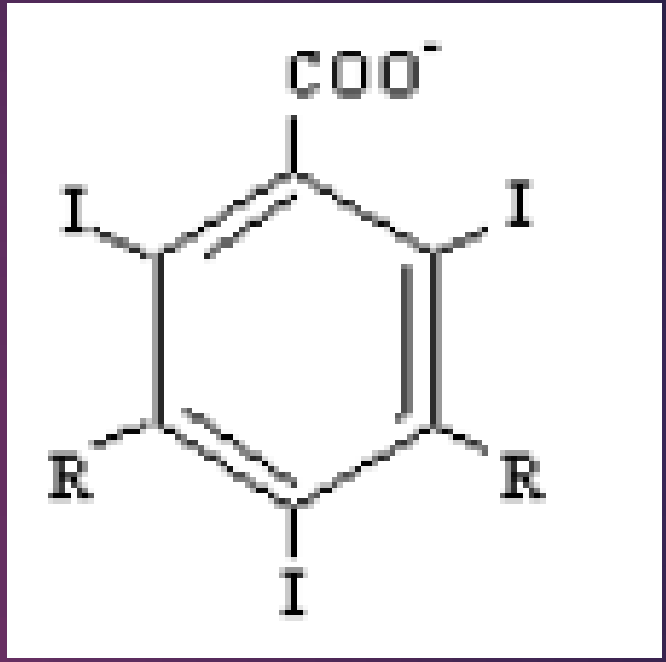

- Ionic high osmolar RCMs not used IV
- Retrogrades
- Cheap
- Side effects 10x non-ionic
- Also used to treat tape worms

Ionic Dimer

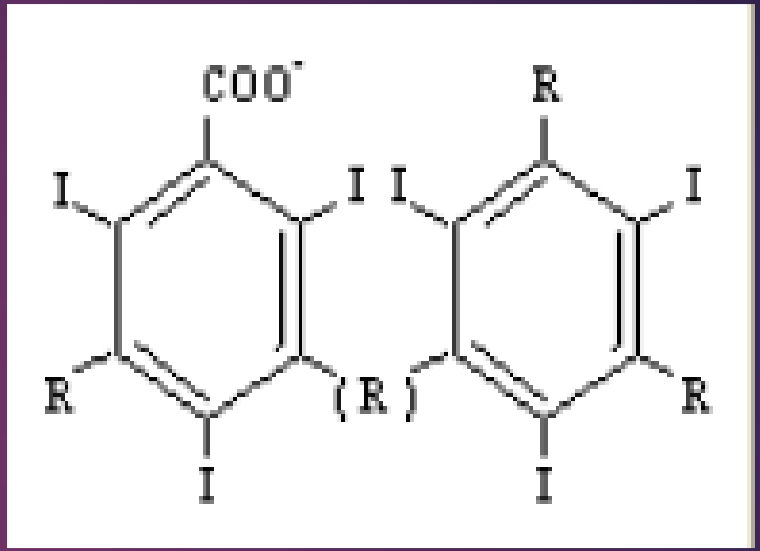

- Iodine atoms per molecule = 6
- Osmotic particles per molecule = 2
- Ratio = 6:2
- Low osmolar = ~600 mOsm/kg water
- e.g. Ioxaglate = Hexabrix (320 mg Iodine/ mL)
- Toxicity - High protein binding

  Electrical charge

Non-Ionic RCM

- Cation replaced by non-dissociating organic chain
- Tri-iodinated non-ionising compounds
- Fewer particles per iodine atom
- Lower osmolality
- Fewer side effects
- More expensive

Non-Ionic Monomer RCM

- Iodine atoms = 3
- Osmotic particles = 1
- Ratio 3:1
- Low osmolar
- e.g. Iohexol = Omnipaque

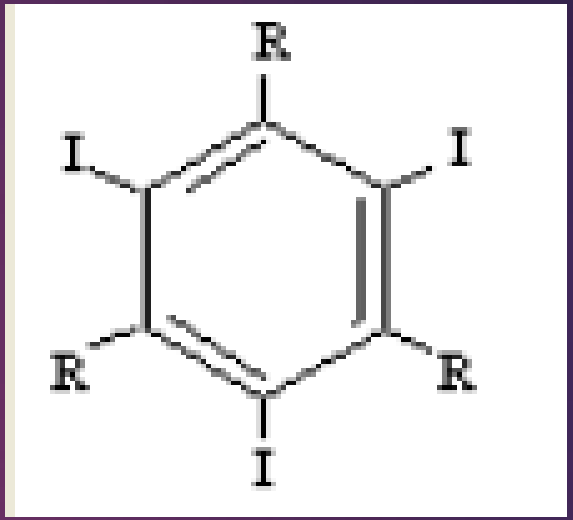

Concentration	Osmolality * Osm/kg H_2O	Viscosity (mPa·s)	
	37°C	20°C	37°C
140 mg I/ml	0.29	2.3	1.5
180 mg I/ml	0.36	3.2	2.0
240 mg I/ml	0,51	5.6	3.3
300 mg I/ml	0.64	11.6	6.1
350 mg I/ml	0.78	23.3	10.6

Non-Ionic Dimer RCM

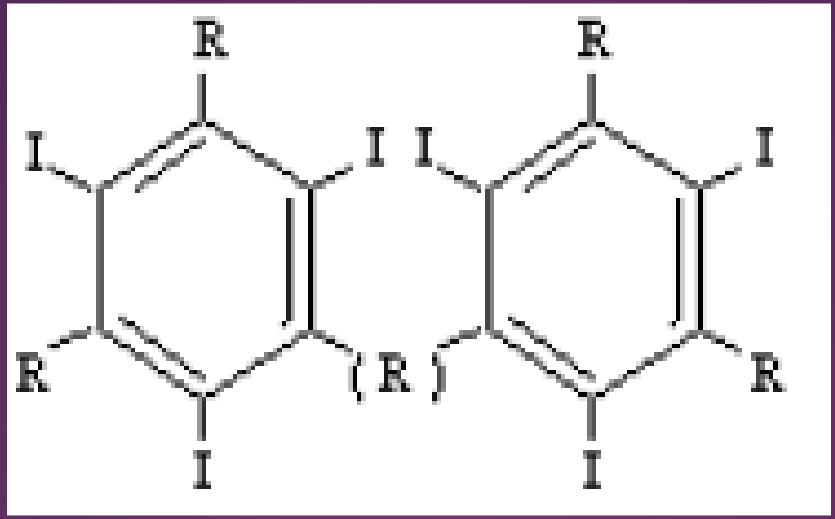

- Iodine atoms = 6
- Osmotic particles = 1
- Ratio 6:1
- Iso-osmolar ~ 300 mOsm
- eg Iodixanol = Visipaque

Structure R = various organic chains	Class	Examples of Media	Iodine atoms to particles ratio	Approx. No. of times more osmolar than blood at 300 mg I/ml
1. Ionic monomer (Na^+ or $MegI^+$) 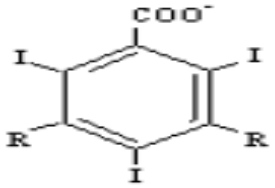	ionic monomer	iothalamate diatrizoate	3 : 2	5
2. Ionic dimer (Na^+ or $MegI^+$) 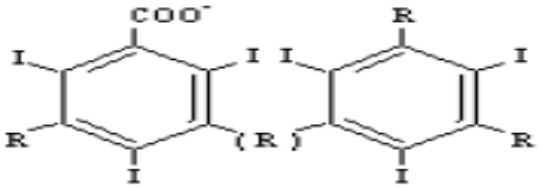	ionic dimer (low osmolar ionic)	ioxaglate	6 : 2 or 3 : 1	2
3. Non-ionic monomer 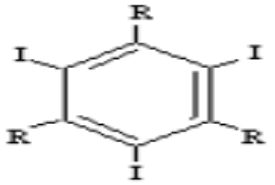	non-ionic monomer (low osmolar non-ionic)	iopromide iopamidol iohexol iopentol ioversol	3 : 1	2
4. Non-ionic dimer 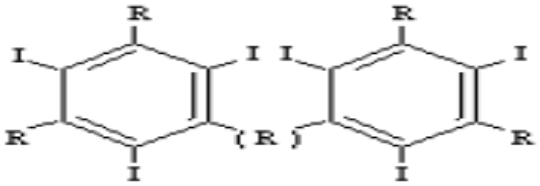	non-ionic dimer	iotrolan iodixanol	6 : 1	iso-osmolar

Points to Remember for RCM

- Radio-opacity
  - Iodine conc. of solution
  - No. of iodine atoms per molecule
  - Conc. of molecules in solution
- Osmolality
  - No. of particles
    - Ionic vs. Non-ionic
  - Low osmolality
    - Fewer side effects / reactions
    - ↓ pain of injection
  - High osmolality
    - Greater risk reactions
    - Causes osmotic diuresis

Points to Remember for RCM

- Dimers
  - Large size → higher viscosity
  - Less lipophilic → more inert
- Strength = conc. of iodine mg/mL
  - Viscosity & osmolality related to conc. of media

Omnipaque Type	Strength mg/mL	Osmolality mOsm/kg H_2O	Viscosity cP@37C	Use
140	140	290	1.5	Video UDS , Retrograde
240	240	510	3.3	Retrograde
300	300	640	6.1	IVU, CTU

Methods of Administration of Contrast Material

- INGESTED
  - (ORAL)
- RETROGRADE
  - AGAINST NORMAL FLOW
- INTRATHECAL
  - Spinal canal
- PARENTERAL (IV, Intrathecal)
  - Injecting into bloodstream
  - (anything other than oral)

BLOOD WORK

LAB TESTS to check function of kidneys prior to injection of contrast

- WATCH THE UPPER LIMITS
- BUN = BLOOD UREA NITROGEN
- Merrills pg 214 range is 8 to 25

  pg 242 range is 10 - 20

  always check with RAD when level above **20**
- CREATININE levels range:
- pg 214 (0.6 - 1.5) pg 242 (0.05 - 1.2)

  always check with RAD when level above **1.2**
- Indicates function of kidneys
- Diseases / dehydration / kidney failure

1. Patient's history per patient's chart

- Elevated creatinine?
  (Normal 0.6 to 1.5 mg/dl)
- Elevated BUN (blood, urea and nitrogen)
  (Normal 8 to 25 mg/100 ml)
- Glucophage (metformin)?
  (Taken for non-insulin dependent diabetes)

To be withheld 48 hours prior to procedure

SEE : PT CARE : Pharmacology 4th Ed Ch.20 (charts p293/p.299)

Contrast media for SPECIAL PROCEDURES

Diagnostic agents that are injected into

- Circulatory System, Joint Spaces, Ducts
- Body orifices/organs: uterus, breast, salivary & lymph glands

SPECIAL PROCEDURS CONTRAST MEDIA

ONLY Water sol.

- Arthrograms
- Myelograms
- Angio/Arterio grams
- Cardiac Cath
- Venograms

Water or OIL

- Hysterosalpingogram
- Sialogram
- Lymphangiograms

- Lasts longer – may cause

FAT EMBOLI

SPECIAL "o-grams"

- Venogram
- Arthrogram
- Sialogram
- Myelogram
- Arteriogram
- Angiogram
- Galactogram
- Hystersalpingogram…….. etc

CONTRAST INJECTION

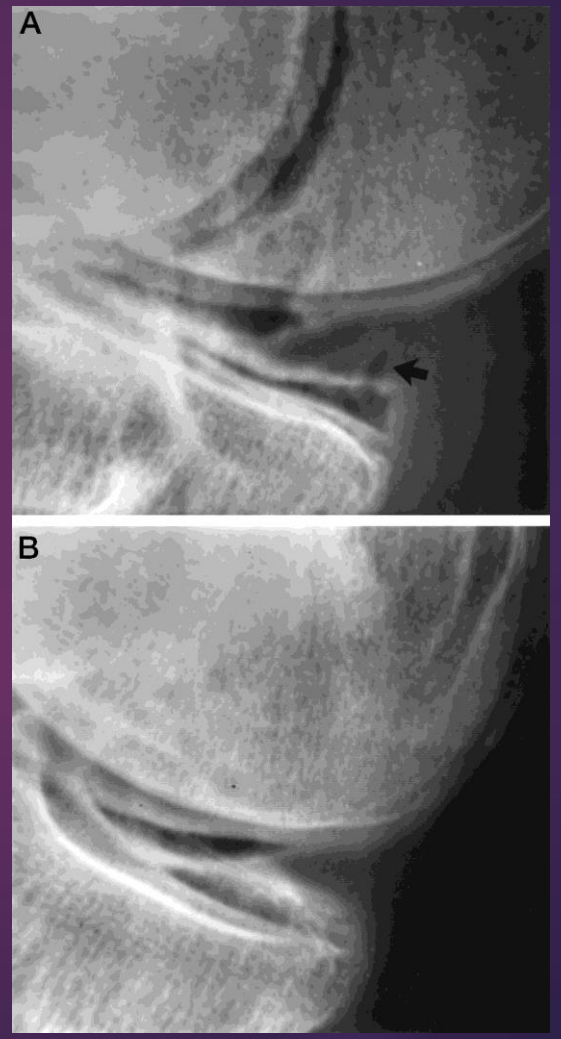

KNEE ARTHROGRAM

SPECIAL PROCEDURS CONTRAST MEDIA

ARTHROGRAMS

- Injected into JOINT SPACES
- IODINE (positive contrast)
  - WATER soluble
  - (Ionic or Non-Ionic)
- AIR (negavitve contrast)

DOUBLE CONTRAST WITH IODINE - HIP Arthrogram

To check fertility

can be oil or water based contrast

Hysterosalpingography (HSG)

- Contrast media study demonstrating uterus and uterine (fallopian) tubes
- Anatomy

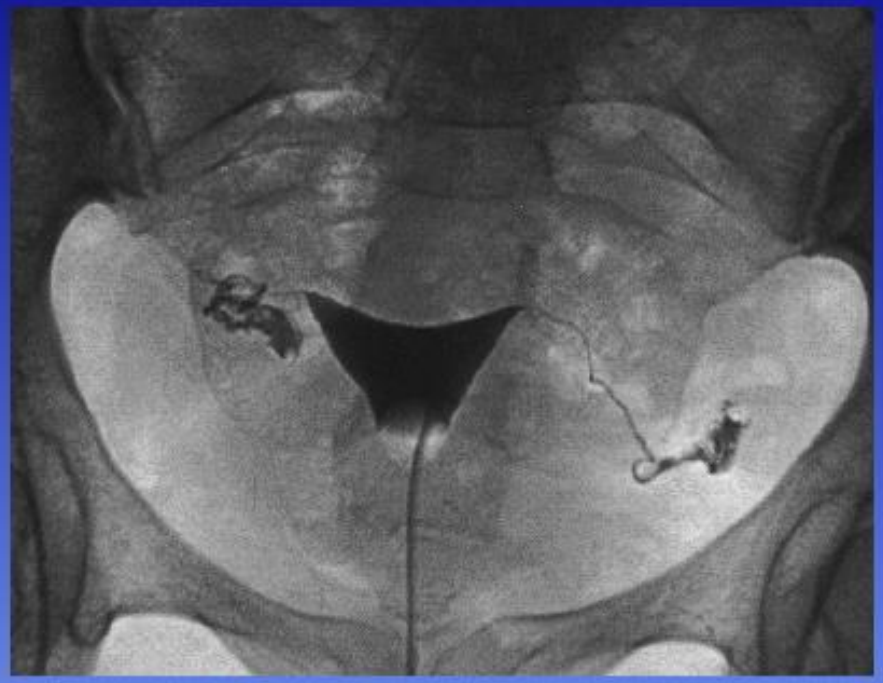

AP HSG radiograph

Myelogram

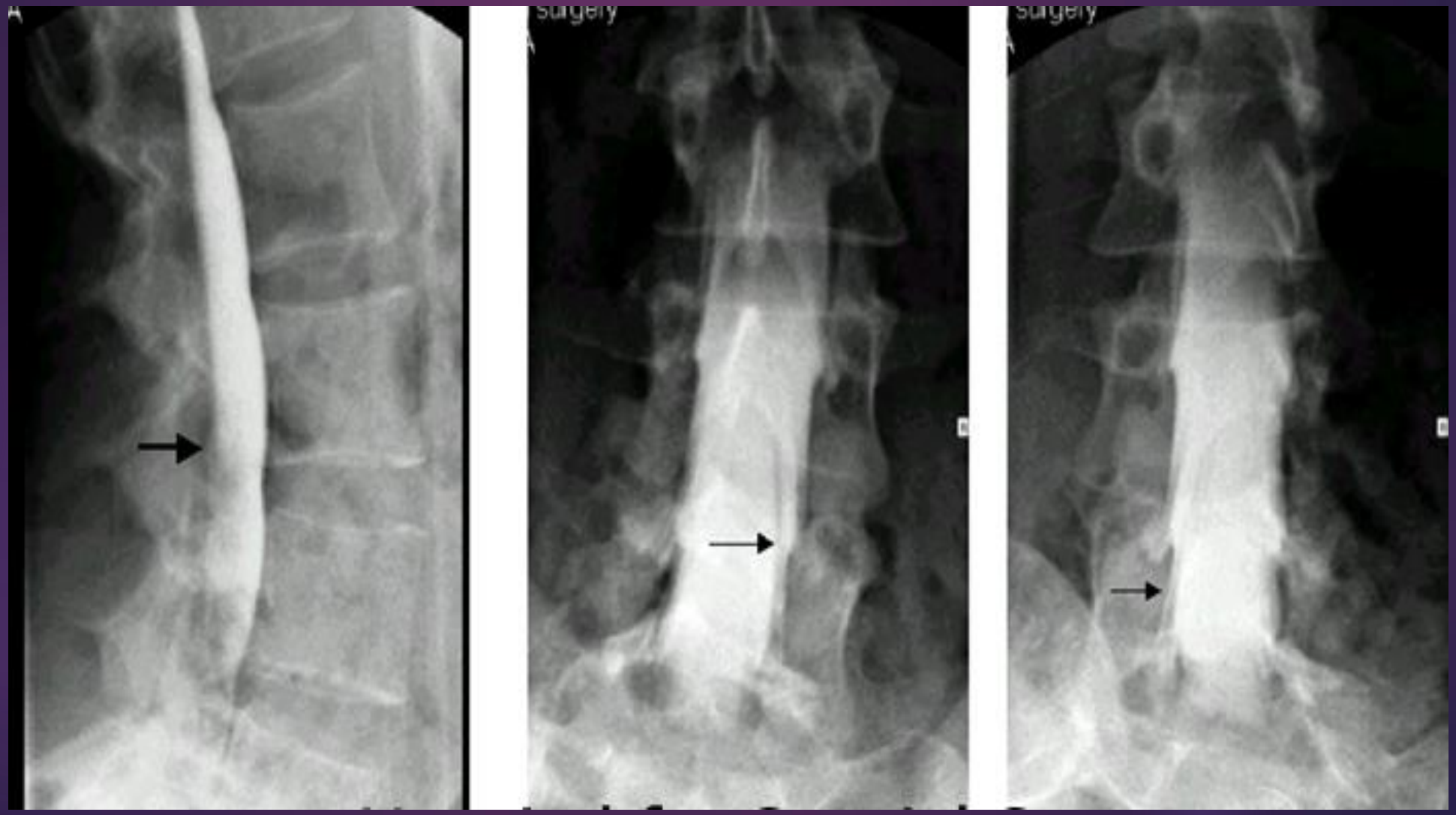

SPECIAL PROCEDURS CONTRAST MEDIA

MYELOGRAMS

- Injected INTRATHECALLY (into the subarachnoid space)
- **Nonionic** water-soluble contrast
- (NO IONIC CONTRAST)

Myelogram Contrast

- Pantopaque was introduced in 1944 as a oil contrast medium
- The first low-osmolar contrast medium to be produced was metrizamide (Amipaque)

- Oil never completely re –absorbed
- (Pre-employment L.sp)

SIALOGRAM

SPECIAL PROCEDURS CONTRAST MEDIA

SIALOGRAPHY

– injected into Salivary Ducts

- IODINE –
  - WATER (ionic or nonionic)
  - OR OIL BASED

  - SINOGRAPHIN (OIL)
  - RENOVUE (WATER)

Galactography - Breast Duct

Cerebral Angiogram

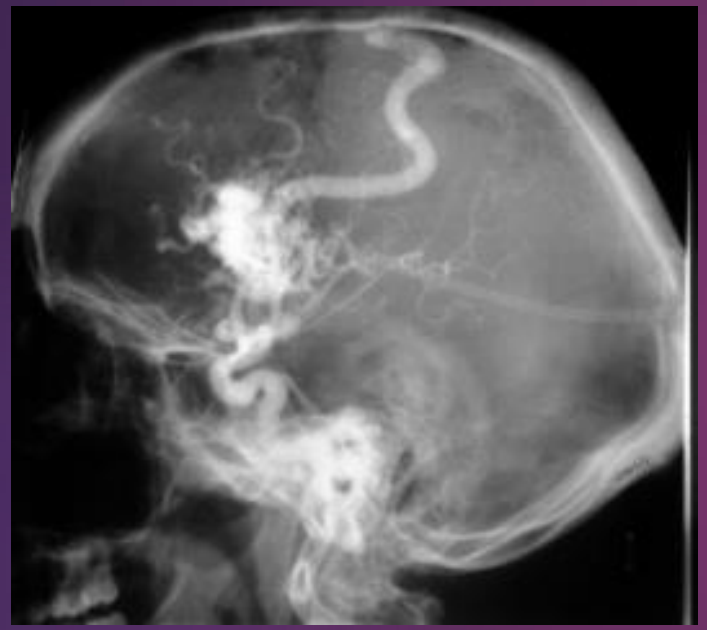

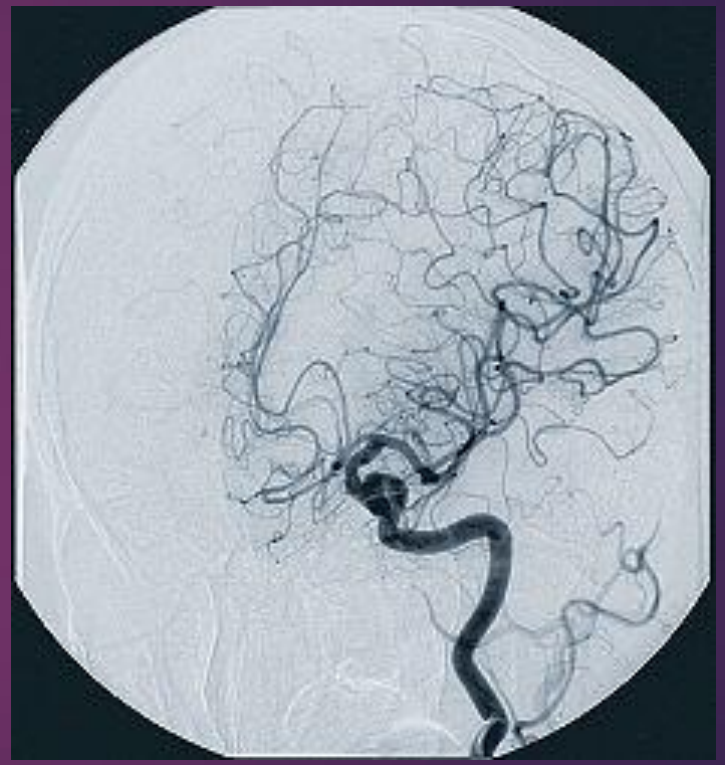

LYMPHANGIOGRAM

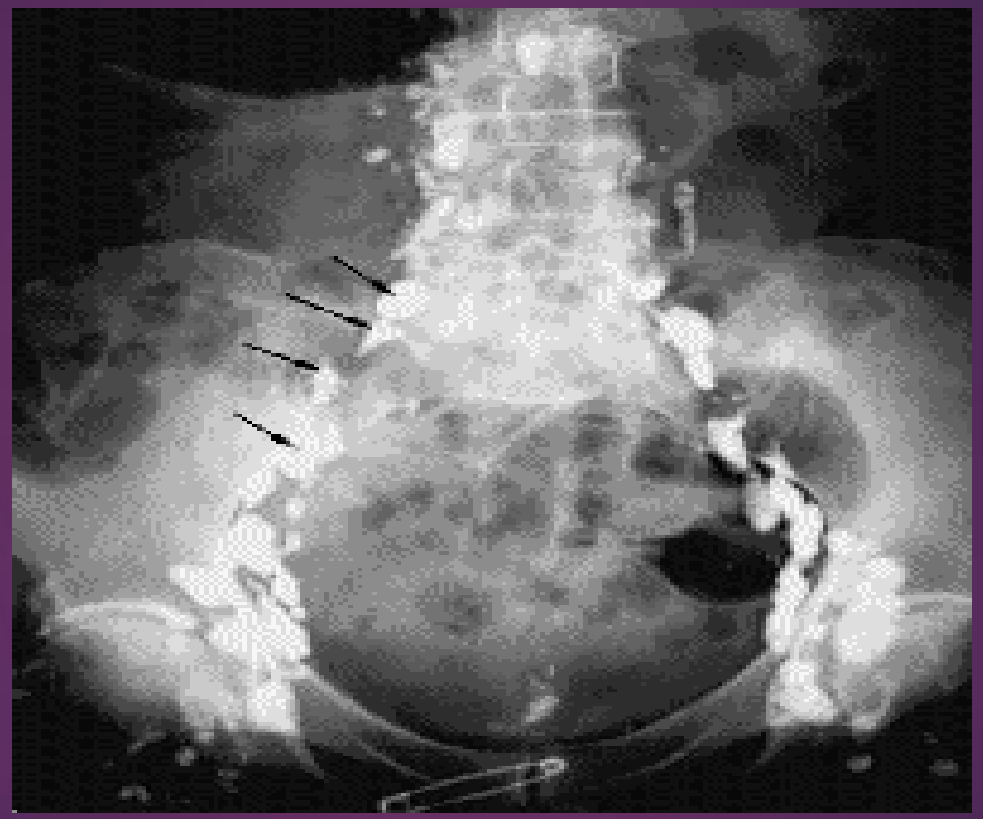

Dacryocystography

Figure 2. Conventional dacryocystography. Normal.

Now largely replaced by CT

SPECIAL PROCEDURES ARE INVASIVE

ALWAYS GET PATIENT'S HISTORY AND CONSENT BEFORE BEGINNING OR GIVING ANY CONTRAST MEDIA

ALWAYS TAKE

A “SCOUT”

BEFORE CONTRAST INJECTION

Why?

MR rast

Medscape®
www.medscape.com
Source: Appl Radiol © 2008 Anderson Publishing, Ltd.

MRI with contrast

Without

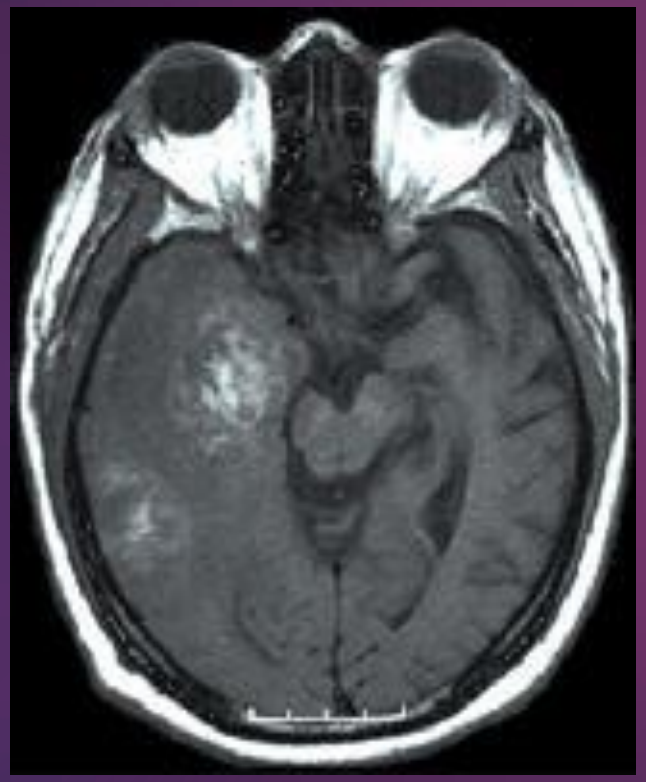

What is the name of the contrast used for MRI ?

Gadolinium z# 64

- Once injected, gadolinium accumulates

in abnormal tissues of the brain and body.

- Provides a greater contrast between normal and abnormal tissues

MORE dilute than used for Radiology

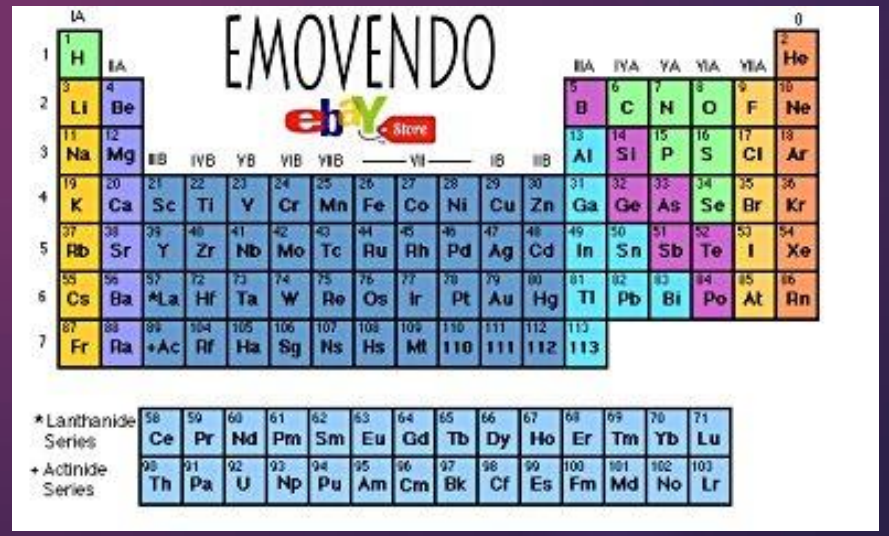

Gadolinium (paramagnetic agent)

- T1 - This tissue-specific time constant for protons, is a measure of the time taken to realign with the external magnetic field.
- Gadolinium decreases T1 relaxation time.
- Enhanced tissues and fluids appear extremely bright on T1-weighted images.
- Provides high sensitivity for detection of vascular tissues (*e.g.* tumors).
- Dynamic Contrast Enhanced MRI more sensitive than T2W images for prostate cancer localization (50% vs 21%; $p = 0.006$) and similarly specific (85% vs 81%; $p = 0.593$).

gadolinium

- On its own gadolinium is toxic to the human body, but when coated in a special chelating agent, it is safe to use.
- When the chelating agent breaks down prematurely, or the kidneys are unable to excrete the gadolinium from the body, gadolinium poisoning can occur

Gadolinium Side Effects

- **With impaired kidney function, gadolinium could lead to a serious and potentially fatal disorder called Nephorgenic Systemic Fibrosis.** (NSF)

- More common conditions associated with exposure includes
- impaired kidney function
- irritation of blood vessels
- facial swelling
- skin conditions, including rashes, itching and hives

Complications

- Minimal nephrotoxicity
- Allergy rare
- Nephrogenic systemic fibrosis
  - Severe delayed fibrotic reaction of tissues (from day of exposure up to 2-3 months)
  - Can be progressive & fatal in around 5%
  - Starts with red, itchy painful swelling on limbs progressing to muscle weakness and contractures.
  - Risk with GFR <60 (Highest if <30)
  - Not reported GRF >60

CT Contrast

- Oral/Rectum
  - – Barium or Iodine
- IV: Iodine

- Usually less dilute
- than for Radiology

CT w contrast

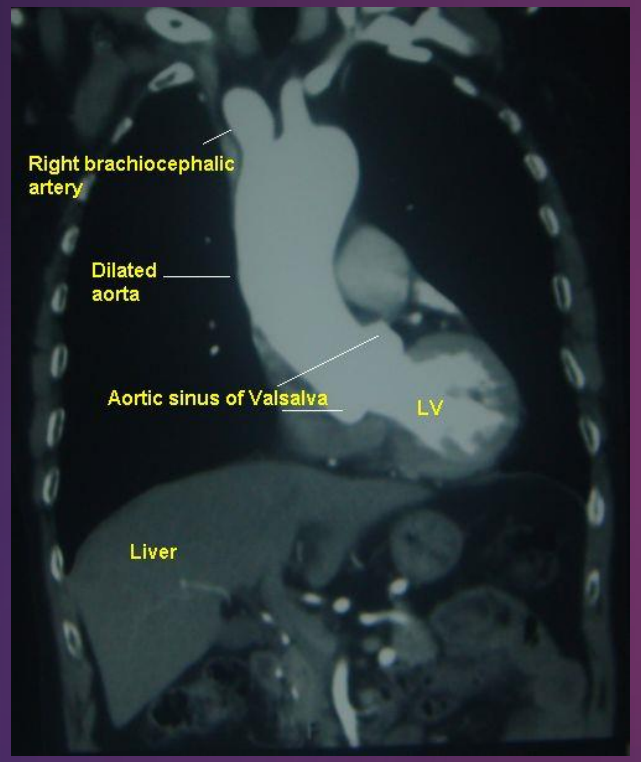

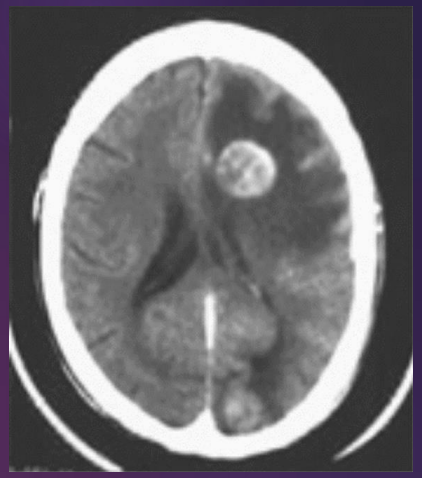

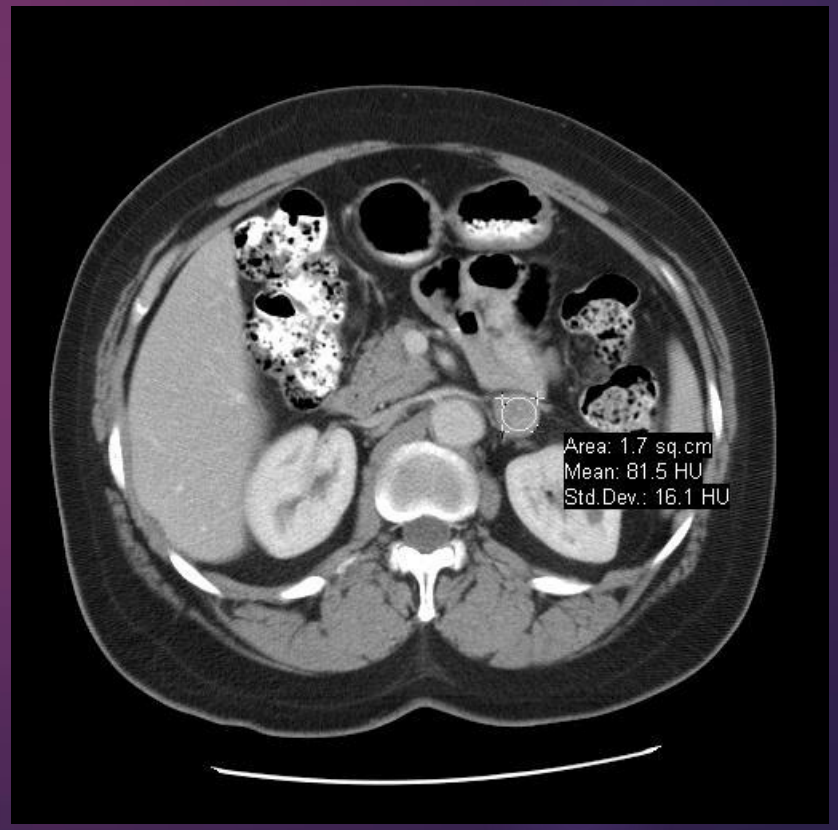

CT Contrast

- **CT Scan Contrast Indications**
- History of tumor, cancer, or surgery
- Looking for infection, inflammation
- Evaluating blood vessels
- Investigate a finding in a scan done without contrast

- **CT Scan Contrast Side Effects**
- Mild to life-threatening allergic reaction
- Flushing/redness and hives
- Shortness of breath
- Nausea, vomitting
- Blood clots
- Dizziness

Ultrasound CM & CEUS

- Alters echo amplitude in ultrasonography
  - Changes in absorption, reflection & refraction
- Encapsulated microbubbles <10μm diameter
- Confined to vascular space
- Increase echo strength up to 300 fold
- Can use targeting ligands to bind to endothelial receptors (integrins & growth facor receptors) enableing microbubble complex to accumultae in area of interest.
- Can derive measures of tumor blood flow and blood volume by employing high mechanical index ultrasonography to destroy micro bubbles in a given region and then determining the rate at which they reappear; a process termed replenishment kinetics
- INcreased sensitivity of TRUSS guided prostate biopsy (38-54% vs. 65-93%)
- Eg: Levovist, Sonovist
- Complications very rare

Lymphotropic Superparamagnetic Nanoparticles

Particles are taken up by macrophages of the reticuloendothelial system and accumulate in lymph nodes.

Passive, cell-specific targeting of the iron oxide nanoparticles to lymph nodes.

Differential cellular content of benign versus malignantly infiltrated nodes make this method suitable for cancer staging.

Lymphotropic nanoparticle enhanced MRI, differences in benign versus malignant infiltration of lymph nodes can be visualised, which adds accuracy to standard MRI beyond criteria based solely upon the size and shape of lymph nodes.

TOXICITY OF CONTRAST MEDIA AND ADVERSE REACTIONS

Toxicity of media

- Major life threatening contrast reaction is rare
  - Non-ionic agents
    - Severe 0.04%
    - Very serious reactions 0.004%
    - Deaths 0.001%

Katayama *et al*, Radiology 1990

What contributes to discomfort, side effects, reactions:

- VISCOSITY – (thick, sticky)

  thicker – harder to inject, more heat and vessel irritation (higher = greater viscosity)

Warming contrast will help

- TOXICITY - (higher = greater viscosity)
- MISCIBILITY - easily mixes with blood
- OSMOLALITY - is a measure of the total number of particles in solution.

Iodinated CONTRAST AGENTS
Adverse Reactions

- Osmolarities higher than body fluids
- Viscous
- Greater chance for contrast reactions
- Anaphylatic shock is the most severe
- Injection of ionic contrast media may lead to hypovolemia.

Hypovolemia

- **basically means low blood volume**
- **Symptoms of hypovolemia may include**
  - **cold hands and feet, light headedness, infrequent urination, increased heart rate, and weakness.**
  - **Low blood volume can result in multiple organ failure, kidney damage, brain damage, and death**

- **hypovolemia** differs from dehydration (which is excessive loss of body water
- **hypovolemia** can lead to dehydration

Toxicity of media

- Classification of adverse reactions
  - Idiosyncratic anaphylactoid reactions
    - Not dose related
  - Non-idiosyncratic chemotoxic reactions
    - Dose dependent
    - Molecular toxicity
    - Physiological characteristics
    - Mechanisms
      - Chemotoxic
      - Hyperosmolar

Idiosyncratic - Not dose related

Mild	Intermediate	Severe
Mild urticaria	Extensive urticaria	Cardiopulmonary collapse
	Angio-oedema	Pulmonary oedema
	Bronchospasm	Bronchospasm
	Layngospasm	Laryngospasm
	Hypotension	Hypotension

Non-idiosyncratic - Dose dependent

Minor	Intermediate	Severe
Tachy/brady	Oliguria/anuria	VT/VF
	Azotaemia	MI
	Myocardial ischaemia	
	Arrhythmia	
	Bronchospasm	

Iodinated Contrast Media: Adverse Reaction Summary, 1985–1999

- Mild and moderate adverse events more common with ionic contrast material than with non-ionic
- Severe reactions are seen equally with ionic and non-ionic contrast material but differ in type:
  - Ionic – allergic-like
  - Non - ionic cario-pulmonary decompensation

Previous reaction to CM

- Exact nature of ADR
- Agent used
- Re-examine need for RCM study
  - Risk/benefit ratio
  - Alternative - non-contrast, USS, MRI
- If RCM necessary
  - Use different RCM
  - LOCM / iso-osmolar CM
- Prophlactic steroids - no conclusive evidence

Other known allergies - Atopy and CM

- Increased risk – 2 x
- Confirm previous type of allergic reaction
- Re-examine need for RCM study
  - Risk/benefit ratio
  - Alternative - non-contrast, USS, MRI
- If RCM necessary
  - Use different RCM
  - LOCM / iso-osmolar CM

Asthma and CM

- ↑ Risk severe ADR
- Confirm diagnosis
- Determine if well controlled
- Defer if exacerbation or poor control
- Rx as per previous reaction

Metformin therapy

- Excreted exclusively via kidneys
- Can cause/exacerbate lactic acidosis
- Normal Cr range of eGFR – don't stop
- If out of range consult stopping for 48 hrs with referring clinic

Standards for intravascular contrast agent administration to adult patients.

Risk factors for adverse intravenous contrast media reactions

- Use a non-ionic low or iso-osmolar agent
- Maintain close medical supervision
- Leave the cannula in place and observe the patient for 30 minutes
- Be ready to treat promptly any adverse reaction and ensure that emergency drugs and equipment are available

Standards for intravascular contrast agent administration to adult patients. RCR 2010

Figure 1 Anaphylactic Reactions: Treatment Algorithm for Adults by First Medical Responder

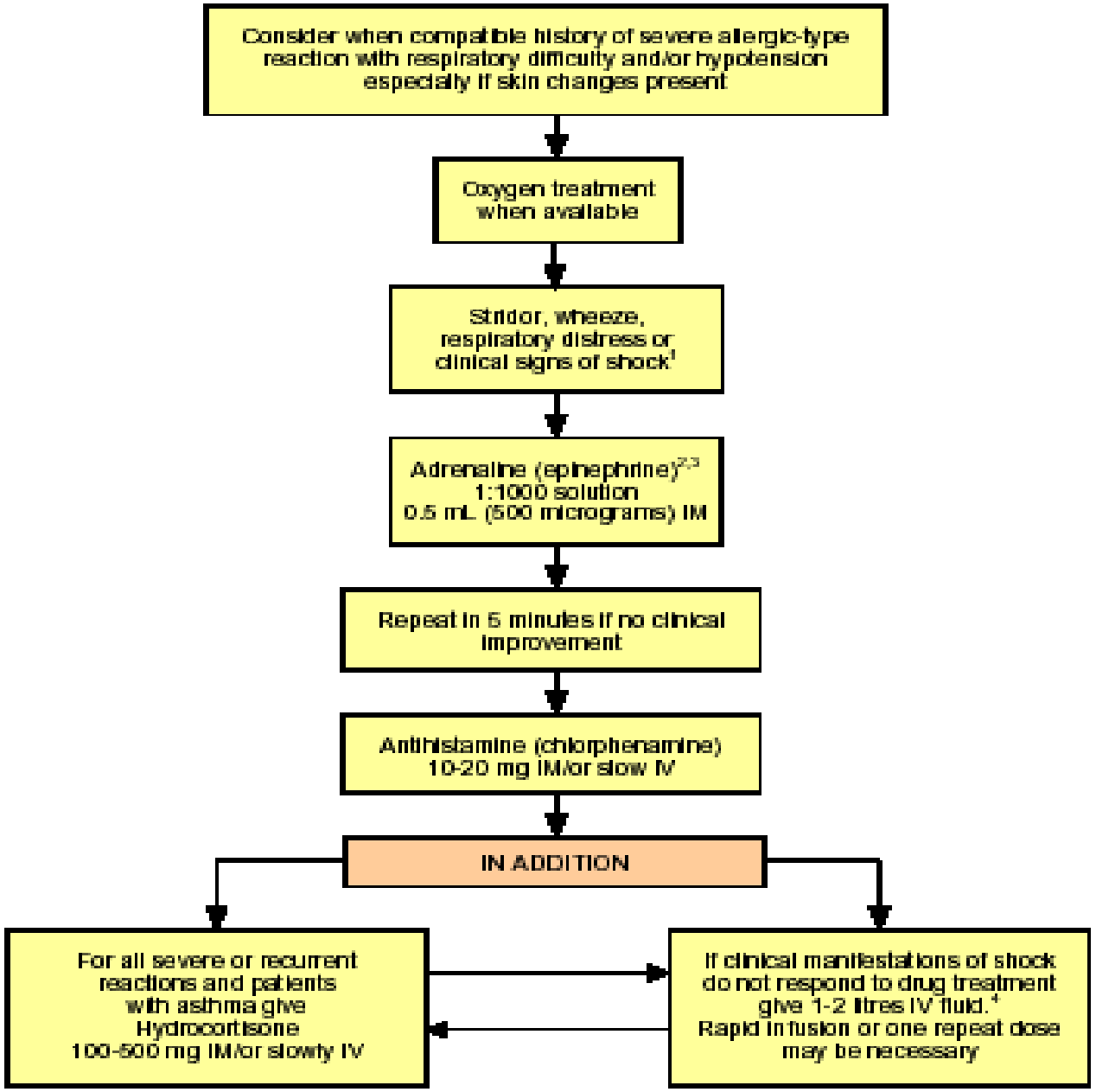

Mild Reactions
(Self Limiting)

- Symptoms
  - –Nausea and vomiting
  - –Hives (urticaria)
  - –Itching
  - –Sneezing
  - –Extravasation
  - –Vasovagal response

Copyright ©2001 Mosby, Inc.

Moderate Reactions
(Requires medication)

1. Excessive urticaria
2. Tachycardia
3. Giant hives
4. Excessive vomiting

Copyright ©2001 Mosby, Inc.

Severe Reactions !
(Requires Immediate Treatment)
• Very low B/P
• Cardiac or respiratory arrest
• Loss of consciousness
• Convulsions
• Laryngeal edema
• Cyanosis
• Difficulty in breathing
• Profound shock
Copyright ©2001 Mosby, Inc.

Reaction classification

- Immediate reactions were defined as those occurring within the department (within one hour)
- Delayed as those occurring between the time the patients left the department and up to seven days later

Delayed Side Effects to Contrast

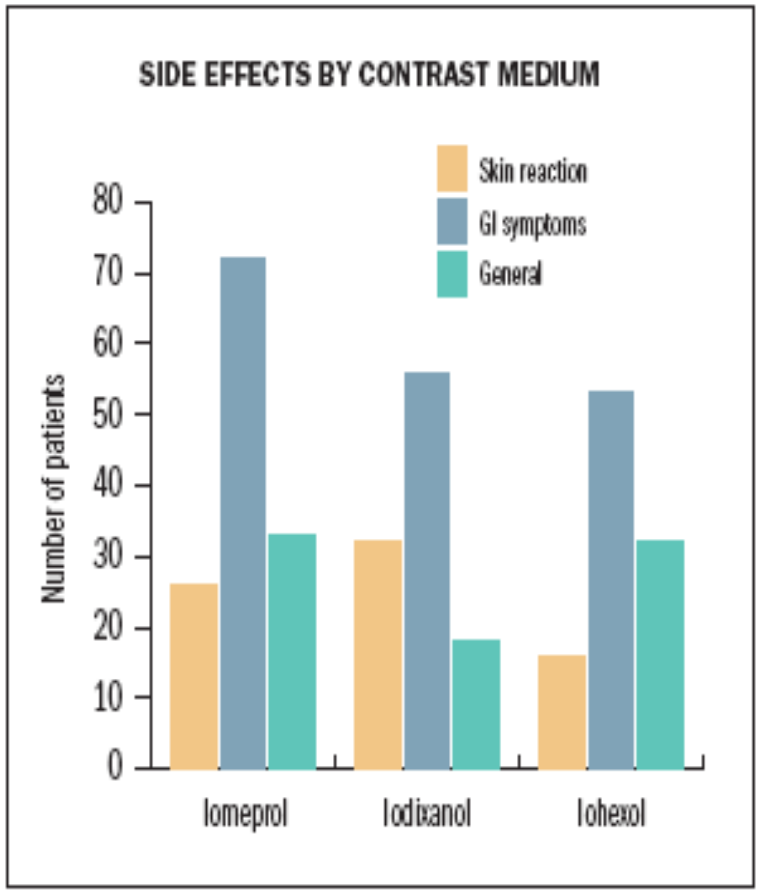

Number of patients developing skin, gastrointestinal, and general side effects following administration of different contrast media.

- Skin effects included itching, rash, and hives.
- Nausea, vomiting, and diarrhea were the gastrointestinal side effects
- General side effects included headache, dizziness, and fever.
- Infants and patients older than 60 years are at increased risk of developing a side effect.

GOOD PATIENT HISTORY

- Kidney problems
- Diabetes
- Heart conditions
- Allergies
- Asthma

- Previous reaction
- Current medications
- Beta Blockers
- Antihypertensive medications

- VITAL SIGNS

CONTRAST REACTIONS

- **General**
- > 10 million diagnostic procedures per year
- Conventional ionic contrast reactions - 10%
- 1 in 1000 severe

Contraindiatons for Contrast

- Renal Failure (Check BUN & Creatinine)

  Elevated levels could cause renal shutdown
- Anuria (no urine production)
- Asthma (possible allergies)
- Hx of Contrast Allergy / Reactions
- Diabetes - get a hx of medications taken
  - glucophage must be stopped 48 hrs before contrast injection
- Multiple Myeloma

MORE Risk Factors for Contrast Reaction

- Older patient age
- Allergic Rhinitis, medication or Food Allergy
- Cardiovascular disease

CONTRAINDICATIONS

- Pregnancy (risk of fetal Thyroid toxicity)
- + Radiation concerns

- Allergic Reaction
- Pathologic Conditions
- Infection

Allergic to Iodine

- General Rule:
- No Iodine Contrast will be given
  - Pre – medication is available
- May or may not react if previous iodine given

Aseptic Technique for injection

betadine scrub

Contains iodine

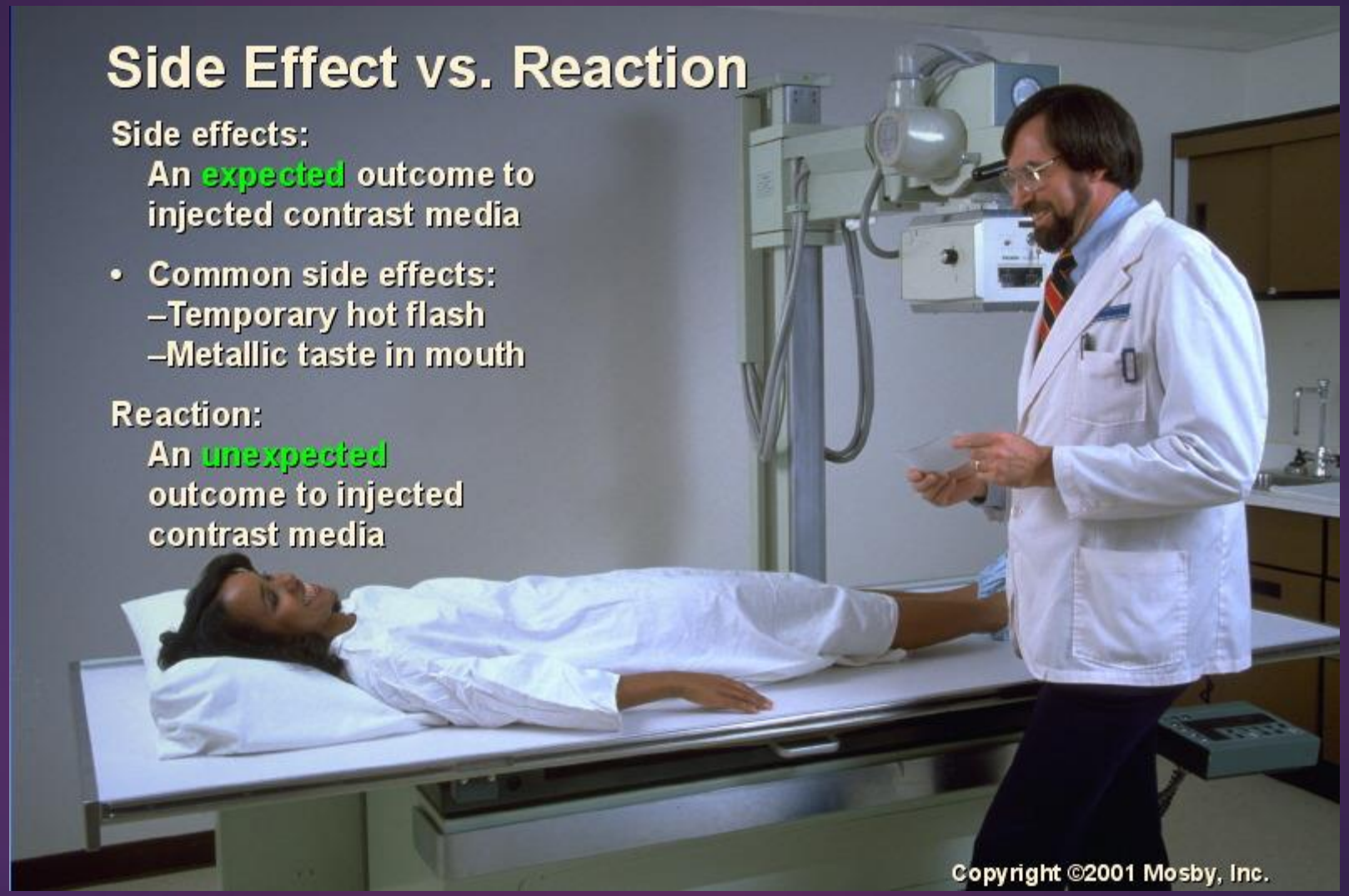
Side Effect vs. Reaction
Side effects:
An expected outcome to injected contrast media
• Common side effects:
–Temporary hot flash
–Metallic taste in mouth
Reaction:
An unexpected outcome to injected contrast media
Copyright ©2001 Mosby, Inc.

REACTIONS & Treatment

USUALLY WITHIN FIRST 5 MINUTES**

- Nausea & Vomiting & Urticaria
- Hypotension (bradycardia)
- Hypotension (tachycardia)
- Bronchospasm
- Anaphylactoid
- Seizures

- Extravasation

Categories of Adverse Reactions

MILD

- nausea, vomiting
- Uticaria (hives) rash – itching
- Flush face – feeling of warmth
- Headace, Chills, Anxiety
- Diaphoresis

Treatment – does not usually get worse

Watch patient and reassure

(cool cloth on forehead, emesis basin

MODERATE

- Hypotension (bradycardia)
- Hypertension (tachycardia)
- Dyspnea
- Bronchospasms /wheezing
- Laryngeal Edema

TREATMENT:

Needs immediate treatment –GET RN/RAD

Needs Meds* – (Keep IV line in)

could lead to severe reactions

SEVERE

- Laryngeal edema
- Convulsions
- Profound hypotension
- Clinically manifested arrhythmias
- Unresponsiveness
- Cardiopulmonary Arrest

PROMPT TREATMENT !

Rx for REACTIONS

have ready on Emergency cart or Crash Cart

- UTICARIA (HIVES) –

  Benadryl (diphenhydramine)

  Vistaril (hydorxyzine)

  Tagament or Zantac

- Facial/Laryngeal Edema/Bronchospasms

  Epinephrine , Oxygen

Contrast Reactions/MYTHS

- not caused by iodine
  - Ionic vs non ionic - binding elements
- not related to shellfish
- not true allergy (no drug-antibody)
- mechanism remains unknown

Anaphylactoid (idiosyncratic)

- unpredictable
- dose independent
- prevalence 1-2% (0.04 - 0.22% severe)
- fatal 1 in 75,000

RENAL TOXICITY

- (increased serum creatinine > 0.5 mg%)
- 2-7%
- 5 – 10 x increase with pre-existing renal insufficiency
- direct relationship between serum creatinine and likelihood nephrotoxicity
- Hydrate 100 ml/hr Normal saline 4 hrs prior to procedure, continue for 24 hours

GLUCOPHAGE

- Pt is DIABETIC = oral diabetic agent

- MUST STOP __ DAYS BEFORE EXAM
- withhold drug for 48 hrs after contrast administration
- patients with renal insufficiency may develop lactic acidosis
- The signs of lactic acidosis are deep and rapid breathing, vomiting, and abdominal pain

Pre-Medications

- Steroids (Prednisone)
- Benadryl (diphenhydramine)
- Epinephrine

EXTRAVASATION

- Contrast material has seeped outside of vessel
- Local redness and swelling
- Apply WARM Compress 1st 24 hours
- Cool compress for swelling

EXTRAVASATION

- The act of injecting a drug/contrast into an area other than the vessel (soft tissue)

- RTA BOOK: Pharmacology Chapter
- Defines as: Discharge or escape of fluid from a vessel into the surrounding tissue that can cause localized vasoconstriction, resulting in sloughing of tissue and tissue necrosis if not reversed with an antidote.

Extravasation of Contrast into soft tissue of arm

A

B

Contrast leaking from bladder

Summary -

- **Delayed side effects persist in IV iodinated contrast media**
- *History of asthma and allergy predisposes patients to increased incidence of adverse reactions*
- Intravenous iodinated contrast agents are generally safe.
- Though the frequency of side effects has fallen significantly since the introduction of nonionic, monomeric contrast agents,however, side effects remain an important issue.
- Late adverse reactions were first recognized in the mid-1980s

Summary of Contrast Reactions

- Anaphylactoid reactions may present with
- mild symptoms such as skin rash, itching, nasal discharge, nausea, and vomiting
- moderate symptoms like facial or laryngeal edema, bronchospasm, dyspnea, tachycardia, and bradycardia
- severe symptoms such as life-threatening arrhythmias, hypotension, bronchospasm, laryngeal edema, pulmonary edema, seizure, syncope, and death

Summary of Contrast Reactions

- Nonanaphylactoid reactions are due to the ability of the contrast media to upset the body homeostasis, especially the blood circulation.
- Increasing iodine concentration increases the risk of these reactions, which is also affected by the volume and route of administration of contrast.
- Larger volumes or intra-arterial administration are more likely to produce a reaction.
- The cardiovascular, respiratory, urinary, gastrointestinal, and nervous systems are most commonly affected by physiologic changes produced by contrast media.
- The symptoms of nonanaphylactoid reactions are warmth, metallic taste, nausea, vomiting, bradycardia, hypotension, vasovagal reactions, neuropathy, and delayed reactions

Thank You